
CASE SUMMARY : AN INTERESTING CASE OF PIERRE ROBIN SEQUENCE

Dr BASANT KUMAR SONI*¹ and Dr LALROCHHUANGA²

*¹ Pediatric Resident (2nd Year), Diplomate of National board, Civil Hospital Aizawl, Mizoram, India.

² Consultant, Department of Pediatrics, Civil Hospital, Aizawl, Mizoram, India.

Abstract

Keywords: *betel nut, tobacco, retrognathia, cleft palate, pectus excavatum, IUGR, mizoram etc.*

Pierre Robin anomaly is a sequence which consists of retrognathia, cleft palate and glossoptosis. Out of total cases, 40% cases are sporadic, however autosomal dominant and autosomal recessive variants are also noted. Best of author's knowledge, there is no case of PRS reported with pectus excavatum and any association with intra-uterine growth retardation is not yet established. Risk factors of PRS are still not known.

Case report :

Baby of Lalthasangi, a 3 days old baby boy admitted in Civil Hospital Aizawl Mizoram (India) with mother complaining of baby not feeding well since birth with occasional nasal regurgitation of feeds.

Birth history

Baby born by LSCS (Indication: Post CS/ active leaking/ pregnancy induced hypertension) in Civil Hospital Aizawl. Baby cried immediately at birth. Cord clamped after one minute. Baby weighing 2.260 kilogram. Date of birth 20/07/18 at 10.25 PM. On routine ward investigation, baby was found to have low sugar level - 30mg/dl which was corrected as per protocol. Intravenous fluid given for two days. However baby went into cold stress and admitted in specialized neonatal care unit.

Antenatal history

Mother is 34 years old, married at 30 years of age, 2nd para, blood group O+, LMP- 05/11/17 and EDD being 12/08/18. There is no history of HIV/TB/hepatitis/syphilis/GDM. She was diagnosed to have transient thyroid problem which was treated with medication. She was also found to have pregnancy induced hypertension. History of fever present in third trimester, low grade around 101.1 degree Fahrenheit, intermittent in nature, lasted for two days and resolved after medications.

Mother's diet history

Mashed vegetables with rice and non vegetarian sometimes which included beef, pork or chicken. She also used to consume betel nut (PAAN/KUVA in local language) and tobacco (KHAINI in local language), 2-3 times a day, regularly, started since 15 years of age however she abstained from betel nut since 2nd trimester till delivery.

Father

44 years

Non consanguineous, no particular illness

Father's diet

Same as mother, in addition he use to smoke 4-5 cigarettes per day since last 20 years.

There is no history of alcohol consumption.

Family history

Paternal relative - Grandfather had hypertension.

Maternal relative - Grandmother died in 2013 because of lung cancer.

Sibling history

1st child – Born in June 2015 by LSCS in Civil Hospital Aizawl, weighing approx 3 kilogram, girl, cried immediately after birth. According to mother, baby was very weak, did not breastfeed well and admitted in SNCU. Baby was diagnosed to have heart disease with cardiomegaly and died at one month of age in hospital. There were no features suggestive of Pierre Robin Sequence.

2nd child – indexed case.

Socioeconomic history

Family lives in a well built (Pucca) house in Aizawl, Mizoram. There are three rooms, one hall, one kitchen and one toilet in house.

Water supply by municipal corporation connection.

Mother is a housewife, 9th standard pass.

Father is a taxi driver, earns 1000 indian rupees per day, 12th standard pass.

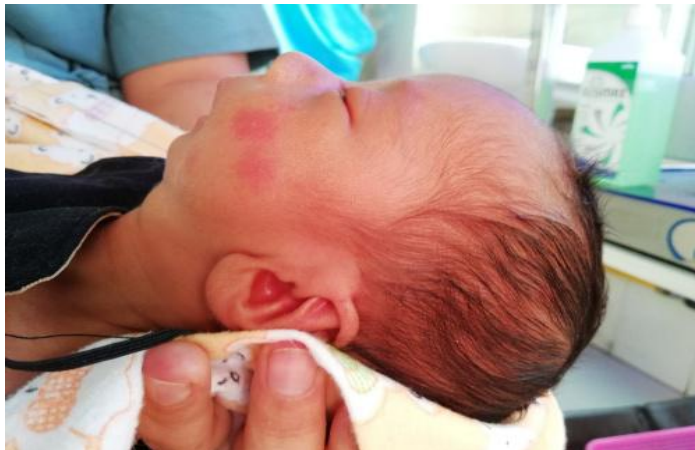

Figure 1: Retrognathia

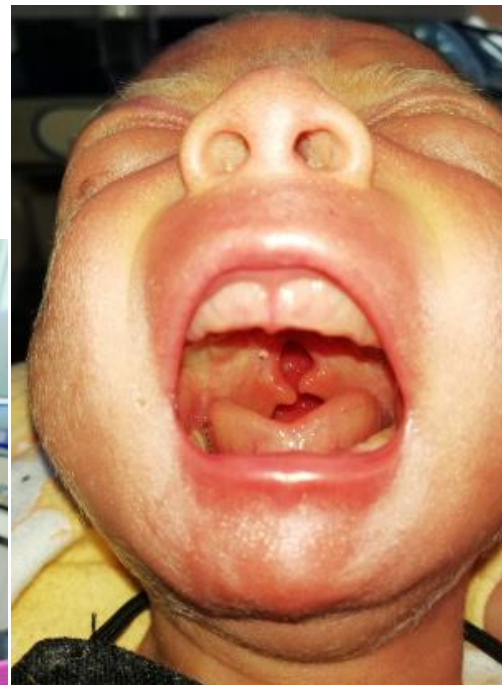

Figure 2: Cleft palate

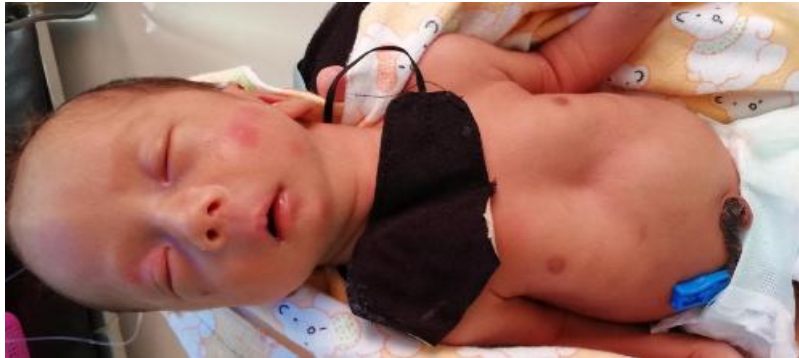

Figure 3 : Pectus excavatum

On examination:

General examination -

Baby is stable looking, Normothermic, Capillary refill time less than 3 seconds, Anterior fontanelle at level, Not pale/cyanosed/no pedal edema, Icterus till abdomen, pectus excavatum present, No evidence of respiratory distress.

Vitals: stable

Local examination -

Retrognathia present, Midline cleft palate defect present which is bifurcating the uvula.

Diagnosis – SINGLE BORN/TERM/MALE/IUGR/LBW/2.260KG/LSCS/PIERRE ROBIN SEQUENCE

Conclusion :



Mizoram is a one of the states in north-eastern part of India, bordering Myanmar and Bangladesh where incidence of congenital anomalies is being studied. This patient, according to hospital records, is first of its kind and never seen before in this locality. Associated anomalies like heart disease and thyroid problem were screened and found to be normal in the patient. However, genetic study of parents and child are under consideration.

This case may be useful in future aspect in finding the risk factors of Pierre Robin Sequence, prevention of this anomaly and for correlation of Pierre Robin Sequence with chest anomalies and intrauterine growth retardation.

Acknowledgement:

Author thanks Dr Lalchhuankimi, Head of the Department, Department of Pediatrics, Civil Hospital Aizawl and Medical Superintendent Civil Hospital, Aizawl for their support for research work.

Author Bibliography :

	<p>Dr Basant Kumar Soni Currently he is pursuing DNB course in speciality of pediatrics at Civil Hospital Aizawl, Mizoram.</p> <p>Email: basantsoni1989@gmail.com</p>
	<p>Dr Lalrochhuanga He is a senior consultant in Department of Pediatrics at Civil Hospital Aizawl, which is a NBE accredited hospital in Mizoram. It is an apex hospital in the capital of Mizoram catering huge number of patients per year.</p> <p>Email: drropaedias@gmail.com</p>